



Debulking of laryngeal lesions with COBLATION[◇] technology

PROCISE[◇] LW Wand can be an ideal tool for reducing the mass in various lesion types. It has been demonstrated that COBLATION tissue injury is limited to the lamina propria and healing is comparable with other technologies used in laryngeal surgery.¹

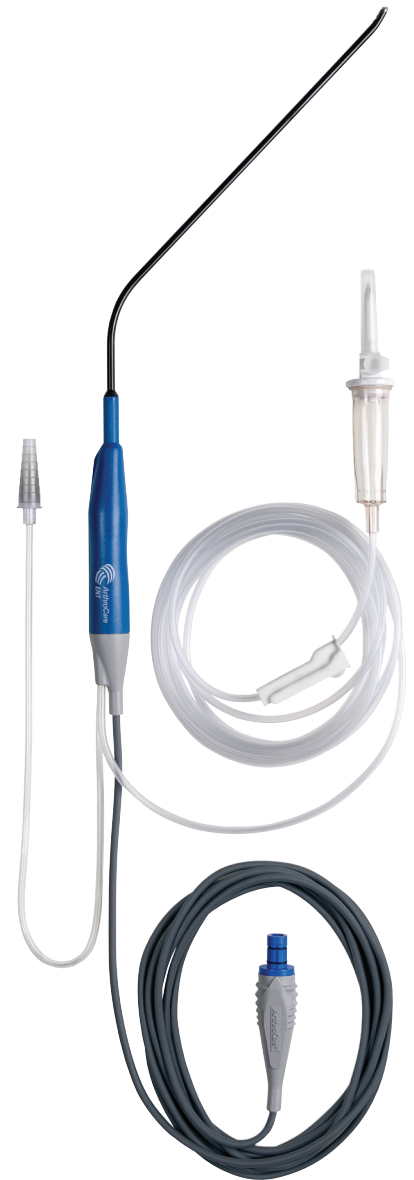Surgical technique

Equipment setup and procedure

- 1 When the PROCISE LW Wand is connected to the Controller, the default settings of Ablate 7 and Coag 3 should appear on the COBLATOR[◇] LEDs respectively. The settings of Ablate 5 and Coag 3 are optimum for treatment of papillomas.
- 2 Connect the Wand's suction tubing to the operating room suction separate from the Yankhaeur. Suction should be set to approximately 250mmHg.
- 3 Set the saline flow to a minimal intermittent drip. Very little saline is required, especially when treating papilloma lesions.
- 4 To ensure optimal visualization throughout the procedure, the laryngeal COBLATION Wand can be used with standard laryngoscopes. Use the largest laryngoscope that can be accommodated. Particularly useful are those with proximally and distally adjustable blades. Standard cuffed microlaryngeal tubes are adequate for protection of the lower airways from any excess saline. This can be aided by gentle packing above the balloon with wet cottonoids.
- 5 The malleable shaft of the Wand can be gently bent if necessary to allow for direct access to the anatomy. Care should be taken not to over-bend the Wand, especially at the tip.

Note: Recent studies about airway fires suggest that using COBLATION technology in place of traditional electrosurgical or laser devices during oropharyngeal surgery significantly reduces the risk of igniting an airway fire due to the low heat generated and the lack of spark or ignition medium under normal operating circumstances.^{2,3,4} Special endotracheal tubes used with lasers are not necessary.

Venturi ventilation has also been used successfully in conjunction with COBLATION technology. A "head down" (Trendelenberg) position should be utilized to ensure any excess saline flows into the pharynx and not in the trachea.

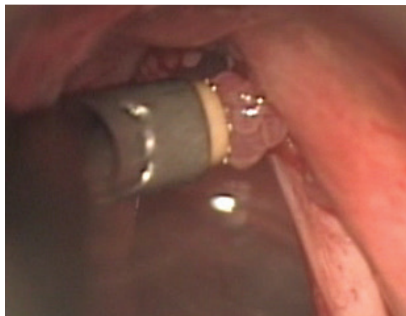

Treatment technique for papilloma lesions

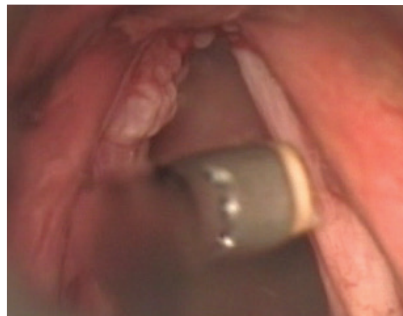Note: Treatment goal is to temporarily restore optimal airway and voice, while minimizing underlying tissue fibrosis. This disease cannot be cured via surgical intervention.

- 1 The target tissues are first dabbed with cotton soaked in 1:1000 epinephrine to reduce bleeding.
- 2 Ablate setting of 5 and Coag setting of 3 are best suited for delicate papilloma work where relatively dry fields aid meticulous removal and coagulation use is minimal.
- 3 Papilloma lesions are best treated using the suction on the Wand to pull the lesion gently away from the underlying tissue. The lesion can then be ablated with minimal trauma to the underlying tissue.

Note: Use caution and ablate in short bursts (0.25 second to 0.5 second) using quick on and off depressions of the yellow Ablate foot pedal.

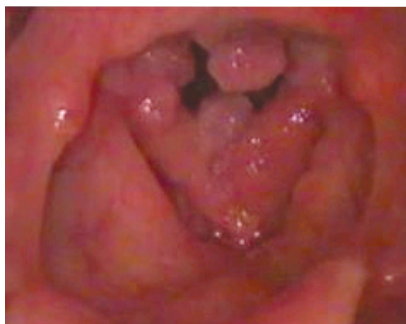

Pulling lesion away from the wall using Wand suction

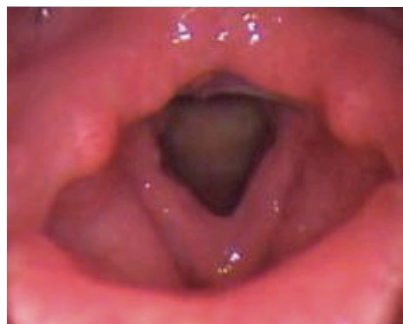

Wand in contact with sessile papilloma lesion

- 4 Keep the active portion of the electrode tip within vision and avoid contact with any non-targeted tissue.
- 5 Minimal bleeding may occur in this treatment process. If any bleeding is encountered, it can be controlled with short (0.5 second) bursts of coagulation set on 3. This setting is adequate for any size of vessel found in this condition and should not be increased to avoid any chance of excessive heating of the underlying tissue.



Before COBLATION® technology treatment



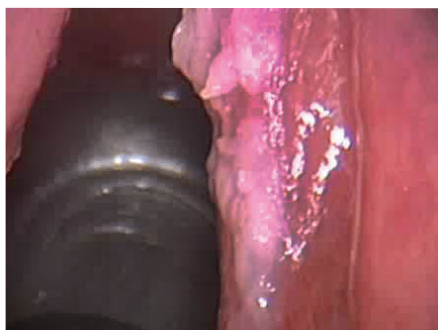
After COBLATION technology treatment



PROCISE® LW laryngeal Wand offers a unique screen electrode design. Outer diameter at tip is 3.8mm.

Debulking of tumors

- 1 After adequate visualization, removal of remaining excess tissue can be accomplished using the PROCISE[®] LW Wand to excise the tumor near the base using a gentle brushing motion.
- 2 With Coag set on 3, any bleeding can be controlled.
- 3 Further reduction of residual lesions can then be performed by surface ablation on settings 7 to 9 until the desired result is achieved.



Tumor

References

- ¹ Original research –Abstract Presented AAO-HNSF 2008- Bipolar Radiofrequency Ablation Eliminates the Risk of Airway Fire in a Mechanical Model: Soham Roy, Lee P Smit
- ² Smith LP, Roy S. Operating room fires in otolaryngology: risk factors and prevention. Am J Otolaryngol. Article in press (Epub 2010 Apr 14).
- ³ Roy S, Smith LP. Device-related risk of fire in oropharyngeal surgery: a mechanical model. Am J Otolaryngol. 2010 Sept;31(5):356-359. This article references preclinical non-human data. As such, results may not necessarily be the same in human procedures.
- ⁴ Matt BH, Cottee LA. Reducing risk of fire in the operating room using COBLATION technology. Otolaryngol Head Neck Surg. 2010 Sept;143(3):454-5.

ArthroCare Corporation
7000 West William Cannon Drive
Austin, TX 78735
USA

www.smith-nephew.com

Order Entry: 1-800-797-6520
Order Entry Fax: 1-888-994-2782