

# Tympano-Ossiculoplasty Utilizing the Spiggle and Theis Titanium Total Ossicular Replacement Prosthesis

Brian A. Neff, MD, Franklin M. Rizer, MD, Arnold G. Schuring, MD, and William H. Lippy, MD

**Objective:** Since 1993, titanium prostheses have been used in Europe as a biocompatible implant for ossicular reconstruction. More recently, the titanium ossicular prosthesis has become more widely available in the United States as a newer means of surgical restoration of hearing. We will review the hearing results of patients who have undergone tympano-ossiculoplasty using a titanium total ossicular replacement prosthesis (TOP). We will compare these results to our previously published results using the porous polyethylene TOP. **Methods:** Retrospective review in a tertiary otologic practice. **Results:** Eighteen patients underwent tympano-ossiculoplasty with a titanium TOP. Among these patients, 10 cases involved revision of a previously placed ossicular prosthesis. Hearing results showed that 16 of 18 patients (89%) had closure of the postoperative air-bone gap to within 20 dB, and the average air-bone gap improvement was 23 dB. The average follow-up time was 8 months (range, 2–21 months). The results of this initial evaluation compare favorably with the results that we obtained using a porous polyethylene TOP in which 67% of 133 patients closed the air-bone gap to within 20 dB. **Conclusion:** We have recently begun using the titanium TOP, which has resulted in improved postoperative hearing when compared with the porous polyethylene TOP. In the future, longer follow-up and increased patient numbers will strengthen our conclusions. **Key Words:** Tympanoplasty, tympano-ossiculoplasty, total ossicular replacement prosthesis, titanium.

*Laryngoscope*, 113:1525–1529, 2003

Titanium is a lightweight material with high rigidity and low sound-damping properties, making it an excellent conductor of sound. Additionally, Schwager<sup>1–3</sup> showed that titanium can make for a highly biocompatible middle

ear prosthesis. He reported that the majority of titanium prostheses in both rabbit models and human studies displayed excellent biointegration without histologic evidence of foreign body reaction or inflammation. Because of all of these factors, titanium prostheses have been used in middle ear surgery and ossicular reconstruction in Germany since 1993. Similar European studies have shown improved hearing results for titanium prostheses when compared to a gold or ceramic prosthesis.<sup>4</sup> We compare our results using the titanium total ossicular replacement prosthesis (TOP) to a historical group of our cases using a porous polyethylene TOP.

## MATERIALS AND METHODS

Patient histories, operative reports, and audiographic data of all patients undergoing tympano-ossiculoplasty with a TOP were retrospectively reviewed since the time our institution began using the titanium TOP in January 2000. Eighteen patients had a titanium TOP placed during surgery and were included in this study. Ten of the 18 cases were revisions of various prostheses placed at other institutions. TOPs were used when the stapes superstructure was absent or unsuitable for use. All 18 cases were performed using the same technique described in the technique discussion of this paper. Additionally, all cases in the titanium group as well as the porous polyethylene group were performed by the senior surgeon (FMR).

The following section separates patients into three surgical categories: tympano-ossiculoplasty only, tympano-ossiculoplasty with intact canal wall mastoidectomy, and tympano-ossiculoplasty with canal wall down mastoidectomy. Each of these groups is further broken down into subgroups, including revisions and primary or secondary ossicular reconstructions.

Seven of the 18 cases involved tympano-ossiculoplasties in patients who did not require or had not previously undergone mastoid surgery. Five of these seven cases were revisions of previously placed partial ossicular replacement prostheses (POP) or TOPs. The remaining two cases were primary tympano-ossiculoplasties for hearing restoration. In all of these cases, the ossicular chain was either involved with tympanosclerosis or had been eroded by chronic otitis media.

Eight of the 18 cases were tympano-ossiculoplasties done in patients who had undergone an intact canal wall mastoidectomy for removal of cholesteatoma. Six of these eight cases were second-stage tympano-ossiculoplasties after intact canal wall procedures performed at our institution. In all of these staged cases,

Presented at the Middle Section Meeting of the Triological Society, Indianapolis, IN, January 17–19, 2003.

The Lippy Group for Ear, Nose, & Throat, Warren, Ohio, and The Ohio State University College of Medicine, Columbus, Ohio, U.S.A.

Editor's Note: This Manuscript was accepted for publication May 7, 2003.

Correspondence to Brian A. Neff, MD, The Ohio State University, 456 W. 10th Ave, Suite 4A, Room 4118, Columbus, OH 43210-1282, U.S.A.

Research supported by the Warren Hearing Research Foundation.

we waited 1 year between the removal of cholesteatoma and ossicular chain reconstruction; and furthermore, none of these cases had residual cholesteatoma at the time of the second-stage procedure. The remaining two cases were revisions of previous intact canal wall tympano-mastoidectomies that had already had the ossicular chain reconstructed elsewhere.

Three of the 18 cases were revisions of previous canal wall down procedures that had been done for removal of cholesteatoma. In each of these cases, an ossicular prosthesis had been placed prior to our revision surgery. Revision surgery was done in each of these three cases for hearing restoration, since there was no evidence of residual or recurrent cholesteatoma.

All patients underwent preoperative and postoperative audiometry with the average follow-up being 8 months (range, 2–21 months). The average air-bone gap was calculated using a three-frequency average of 500, 1000, and 2000 Hz, and a four-frequency average of 500, 1000, 2000, and 4000 Hz. Improvement in the speech reception threshold (SRT) was calculated by subtracting the preoperative from the postoperative SRT. Hearing results were tabulated in groups with air-bone gaps as follows: 0 to 10 dB, 11 to 20 dB, 21 to 30 dB, and greater than 30 dB. These data were then compared with the data from a historical control group of 133 tympano-ossiculoplasties performed with porous polyethylene TOPs (TORP; Xomed Medical Co<sup>TM</sup>, Jacksonville, FL).

### Technique

Our reconstruction method has been described by Brackman et al.<sup>5</sup> and Slater et al.<sup>6</sup> We perform total ossicular reconstruction through a transcanal approach utilizing a tympanomeatal flap. After exposure is adequate, we lyse the tensor tympani tendon to give the tympanic membrane a flatter configuration. We find that this helps stabilize the placement of the prosthesis and the cartilage interposition graft. Next, the stem of the titanium prosthesis is trimmed to an appropriate length. We used a Spiggle and Theis (Micromedics, Inc., Eagan, MN) titanium total prosthesis, which comes in 7.0 and 7.5 mm lengths and on which the stem is marked with grooves every 1 mm (Fig. 1). Thus, prostheses can be cut to a desired length in 0.5 mm increments. The proper length of the prosthesis is judged to be just below the level of the scutum in an intact canal wall and just above the level of the facial ridge in an ear in which the canal wall was removed previously. This will allow the proper amount of tension on the prosthesis once the tragal cartilage is placed between the tympanic membrane and the head (platform) of the prosthesis. After the stem of the prosthesis is cut to length, a small drop of water is placed into the hole of the shoe, and the shoe is placed onto the stem of the prosthesis. The shoe is prevented from sliding off of the prosthesis by surface tension. The next step involves harvesting tragal cartilage through an incision placed 4 to 5 mm medial to the lateral tip of the tragus. The cartilage that is removed is cut into a circular platform that is 5 to 6 mm in diameter. We bevel the edge of the cartilage to allow smoother contact with the tympanic membrane. After finishing with the cartilage, we place the shoe end of the titanium TOP onto the footplate (Fig. 2). The cartilage is then placed between the tympanic membrane and the head of the prosthesis. We use a suction device in one hand to move the prosthesis into a proper position as the other hand uses an angled hook to slide the cartilage posteriorly over the top of the prosthesis (Fig. 3). When the prosthesis and interposed cartilage are in proper position, the prosthesis is totally obscured by the cartilage. With an intact canal wall, the posterior edge of the cartilage should be positioned partially under the scutum. If the canal wall has been previously taken down, the cartilage is placed so that it fits within the confines of the horizontal facial nerve and the facial ridge. Gel-




Fig. 1. Spiggle and Theis titanium total ossicular replacement prosthesis (Micromedics, Inc., Eagan, MN)

foam can be used for stabilization of the prosthesis, but it is not required. Accurate prosthesis placement can be checked with gentle palpation of the cartilage. The cartilage will spring back with palpation; however, the cartilage will feel stiff directly over the prosthesis. Once all of the components are properly placed, the tympanomeatal flap is replaced. The tympanomeatal flap should be slightly tented by the cartilage and prosthesis.<sup>6</sup>

### RESULTS

Eighteen patients underwent tympano-ossiculoplasty with a titanium TOP since January 2000. The patients included 10 women and 8 men who had an

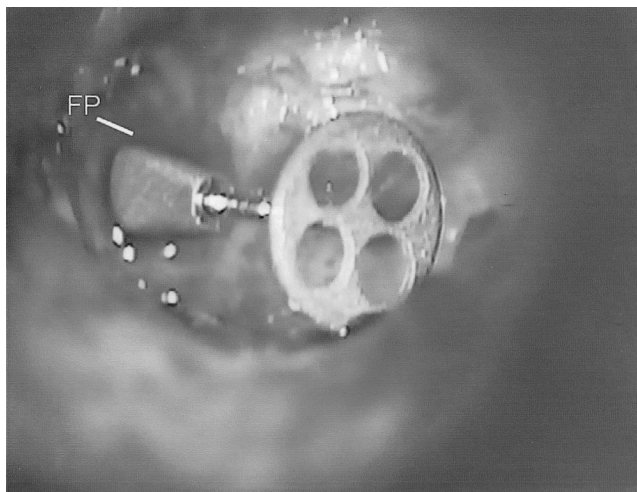


Fig. 2. The prosthesis is placed in the ear with the shoe on the footplate (FP). In this figure, the prosthesis still needs to be stood up and tilted anteriorly.

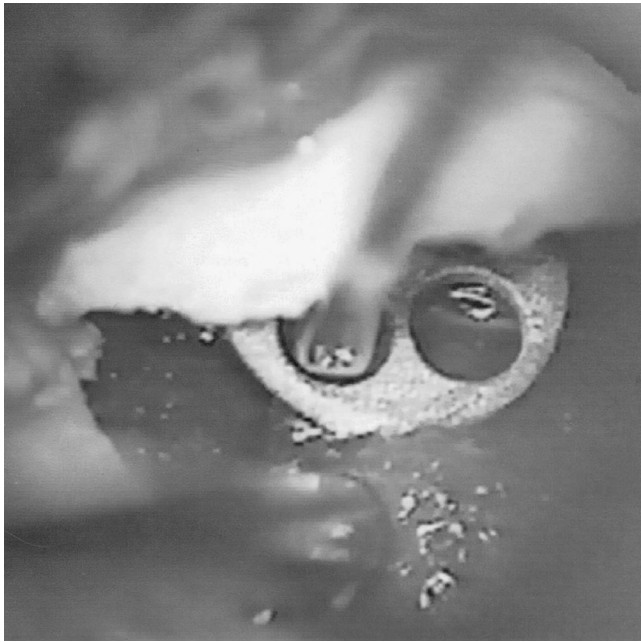


Fig. 3. The tragal cartilage is slipped over the prosthesis. The edge of the cartilage is tucked under the scutum.

average age of 37 years (range, 8–80 years). The average follow-up time was 8 months (range, 2–21 months). In all cases, the prosthesis was sized for the individual patient; however, most patients required a 5 mm prosthesis (range, 4–6 mm). We had no cases of postoperative prosthesis extrusion; however, our follow-up was too short to critically evaluate this complication.

We defined a successful hearing result as those cases in which the patient's postoperative air-bone gap was 20 dB or less. On reviewing our results based on air-bone gaps determined with a three-frequency average (500, 1000, and 2000 Hz), we found that this goal was reached in 16 of 18 patients (89%). Additionally, postoperative closure of the air-bone gap to within 10 dB or less was attained in 11 of 18 patients (61%) (Table 1). The average preoperative air-bone gap was 32 dB, and the average postoperative air-bone gap was 9 dB. The average improvement of the air-bone gap was 23 dB.

When four-frequency average air-bone gaps (500, 1000, 2000, and 4000 Hz) were evaluated for our patient cohort, 16 of 18 patients (89%) still closed the postopera-

tive air-bone gap to less than or equal to 20 dB. However, only 9 of 18 patients (50%) closed the postoperative air-bone gap to less than or equal to 10 dB (Table 2). Moreover, the average preoperative, postoperative, and air-bone gap improvement were 33 dB, 11 dB, and 22 dB, respectively.

The average preoperative SRT was 53 dB, and the average postoperative SRT was 31 dB; thus, the average SRT improvement was 22 dB. All but one patient had an improvement or no change in their postoperative discrimination scores. In the one patient whose discrimination score decreased, the score changed from 88% at 80 dB to 80% at 65 dB. This particular patient's preoperative bone pure-tone average was 40 dB and postoperative bone pure-tone average was 43 dB; thus, the patient did not incur a sensorineural hearing loss.

When evaluating the 10 revision titanium cases separately, the average postoperative, three-frequency air-bone gap was less than 20 dB in 8 of 10 patients (80%) (Table 3). The average air-bone gap was 30.5 dB and the postoperative gap was 12.5 dB. This was an average air-bone gap improvement of 17.5 dB. The average SRT went from 54.5 dB preoperatively to 34 dB postoperatively, for an improvement of 20.5 dB.

There have been reports that titanium prostheses give better hearing results at high frequencies than other prosthesis materials.<sup>4,7</sup> Consequently, we evaluated the average preoperative and postoperative air and bone-conduction thresholds for 4000 Hz (Table 4). The average 4000 Hz air-bone gap preoperatively and postoperatively was 33.9 and 16.9 dB, respectively. This was an average improvement of 17 dB.

## DISCUSSION

Comparison of our previously reported results from 133 cases utilizing the porous polyethylene TOP with the 18 cases utilizing the titanium TOP is summarized in Table 1. Closure of the average three-frequency postoperative air-bone gap to within 20 dB was achieved in 67% of those patients who received the porous polyethylene TOP<sup>6</sup> compared to 89% of those receiving the titanium TOP. Using the Fisher's Exact Test, this difference was found to be statistically significant ( $P = .035$ ). This improvement is likely a result of the improved sound conduction properties of the titanium prosthesis. Additionally, our results are consistent with the results of other series, which have shown excellent hearing results for titanium prostheses

TABLE I.  
Ossicular Replacement Prosthesis\*

Air-Bone Gap, dB	Successful Hearing Result, % (no. of patients)	
	Titanium	Porous Polyethylene
0–10	61 (11/18)	38 (50/133)
11–20	28 (5/18)	29 (39/133)
21–30	11 (2/18)	19 (25/133)
>30	0	14 (19/133)

\*Three-frequency average (500, 1000, and 2000 Hz)TORP

TABLE II.  
Titanium Prosthesis\*

Air-Bone Gap, dB	Successful Hearing Results, % (no. of patients)
	0–10
11–20	39% (7/18)
21–30	11% (2/18)
>30	0% (0/18)

\*Four-frequency average (500, 1000, 2000, 4000 Hz)



TABLE III.  
Revision Total Ossicular Replacement Prosthesis\*

Air-Bone Gap, (dB)	Successful Hearing Result, % (no. of patients)
0 to 10	40 (4/10)
11 to 20	40 (4/10)
21 to 30	20 (2/10)
>30	0 (0/10)

\*Three-frequency average (500, 1000, 2000 Hz)

with closure of the postoperative air-bone gap to within 20 dB in 67 to 79% of cases.<sup>8-10</sup> However, most of these studies combined their results for partial and total ossicular replacement prostheses. Additionally, our average air-bone gap of 23 dB is similar to previously reported 23.2 dB improvement for titanium TOP ossiculoplasties.<sup>11</sup>

It has been postulated that the lighter mass of the titanium prosthesis allows better sound transduction at higher frequencies when compared to other prosthesis materials. Zenner et al.<sup>4</sup> showed that at 3000 Hz, the titanium prosthesis resulted in better hearing than either gold or ceramic prostheses. They showed that 53.3% of 63 titanium TOP cases closed the postoperative air-bone gap to less than or equal to 20 dB. Additionally, Krueger et al.<sup>7</sup> reported that 66% of 15 titanium TOP cases closed the air-bone gap at 4000 Hz to less than or equal to 20 dB. Our study compared favorably to these reports in that 13 of 18 (72%) patients closed the 4000 Hz frequency to less than or equal to 20 dB. The average air-bone gap improvement at 4000 Hz was 17 dB, which is less than the average four-frequency (500, 1000, 2000, and 4000 Hz) air-bone gap improvement of 22 dB for the titanium TOP patients. Consequently, this is still the most difficult frequency at which to close the air-bone gap. Unfortunately, due to the retrospective design of this study, we have incomplete 4000 Hz hearing data for the porous polyethylene group; therefore, a valid comparison with the hearing results associated with the titanium prosthesis at 4000 Hz cannot be made.

The results of our 10 revision cases are given in Table 3. Again, 8 of 10 cases (80%) of revision titanium TOP closed the air-bone gap to less than or equal to 20 dB. The average improvement in the air-bone gap was 17.6 dB. This is similar to previously published data by Downs et al.<sup>12</sup> They reported closure of the air-bone gap to less than

TABLE IV.

4000 Hz Averages for 18 Titanium Total Ossicular Replacement Prosthesis Cases

Average preoperative bone conduction threshold	30.5 dB
Average preoperative air conduction threshold	64.4 dB
Average preoperative air-bone gap	33.9 dB
Average postoperative bone conduction threshold	30.7 dB
Average postoperative air conduction threshold	47.6 dB
Average postoperative air-bone gap	16.9 dB
Air-bone gap improvement	17.0 dB

or equal to 20 dB in seven of nine (78%) revision titanium ossiculoplasties, with an average air-bone gap improvement of 15.6 dB. However, their series of nine patients included results of four titanium POPs.

Although we had no cases of prosthesis extrusion, our series follow-up is too short to evaluate extrusion rates with the titanium TOP. However, several studies have shown very few long-term complications with titanium middle ear prostheses. Dalchow et al.<sup>8</sup> reported an extrusion rate of 0.8% in 790 patients implanted with titanium POPs and TOPs. This is similar to our previously reported 0.89% rate of extrusion in 224 patients who were implanted with porous polyethylene POPs and TOPs.<sup>6</sup>

Of additional clinical importance, titanium middle ear prostheses have been shown to be compatible with magnetic resonance imaging. The titanium TOP used in this study was composed of pure titanium, and similarly composed titanium implants have been safely used for several years as orthopedic prostheses, cranial aneurysm clips, and vascular stents. Several reports have routinely shown these latter implants to be safe in 1.5 Tesla magnetic resonance imaging systems.<sup>13,14</sup> More specifically, Kwok et al.<sup>15</sup> demonstrated that titanium middle ear implants showed no displacement, no temperature change, and very minimal image artifact in a 1.5 Tesla magnetic resonance imaging system.

The advantages of this study are that it compares the titanium prosthesis to the porous polyethylene TOP, which has been used successfully for several years. Additionally, all procedures were done with the same surgical technique and by the same surgeon (FMR), thus eliminating the many variables that are introduced by different surgeons employing different surgical methods. The disadvantages of our study are that follow-up period is too short to ascertain long-term hearing results and prosthesis extrusion rates.

## CONCLUSION

Tympano-ossiculoplasty using a titanium TOP showed a statistically significant improvement in hearing compared to our historical surgical arm utilizing a porous polyethylene TOP (89% vs. 67%). Hearing improvement was also successful in 80% of revision cases in which the titanium TOP was used. Additionally, the study showed that the titanium TOP resulted in closure of the air-bone gap at 4000 Hz in 72% of patients. In the future, we expect that the increased use of titanium TOPs will further support our excellent initial results.

## BIBLIOGRAPHY

- Schwager K. Titanium as an ossicular replacement material: results after 336 days of implantation in the rabbit. *Am J Otol* 1998;19:569-573.
- Schwager K. Titanium as a biomaterial for ossicular replacement: results after implantation in the middle ear of the rabbit. *Eur Arch Otorhinolaryngol* 1998;255:396-401.
- Schwager K. Scanning electron microscopy findings in titanium middle ear prostheses [in German]. *Laryngorhinootol* 2000;79:762-766.
- Zenner HP, et al. Open Tubingen titanium prostheses for ossiculoplasty: a prospective clinical trial. *Otol Neurotol* 2001;22(5):582-9.
- Brackman DE, Sheehy JL, Luxford WM. TORPs and PORPs

- in tympanoplasty: a review of 1042 operations. *Otolaryngol Head Neck Surg* 1984;92:32–37.
6. Slater PW, et al. Practical use of total and partial ossicular replacement prostheses in ossiculoplasty. *Laryngoscope* 1997;107:1193–1198.
  7. Krueger WWO, et al. Preliminary ossiculoplasty results using the Kurz titanium prosthesis. *Otol Neurotol* 2002;23:836–839.
  8. Dalchow CV, Grun D, Stupp HF. Reconstruction of the ossicular chain with titanium implants. *Otolaryngol Head Neck Surg* 2001;125:628–630.
  9. Stupp CH, Stupp HF, Grun D. Replacement of ear ossicles with titanium prostheses [in German]. *Laryngorhinootologie* 1996;75:335–337.
  10. Stupp CH, et al. Three years of experience with titanium implants in the middle ear [in German]. *Laryngorhinootologie* 1999;78:299–303.
  11. Wang X, Song J, Wang H. Results of tympanoplasty with titanium prostheses. *Otolaryngol Head Neck Surg* 1999;121:606–609.
  12. Downs BW, Pearson JM, Zdanski CJ, et al. Revision ossicular reconstruction with the titanium Kurz prosthesis. *Laryngoscope* 2002;112:1335–1337.
  13. Thomsen M, Schneider U, Breusch SJ, et al. Artefacts and ferromagnetism dependent on different metal alloys in magnetic resonance imaging: an experimental study [in German]. *Orthopade* 2001;30:540–544.
  14. Kangarlu A, Shellock FG. aneurysm clips: evaluation of magnetic field interactions with an 8.0 T MR system. *J Magn Reson Imaging* 2000;12:107–111.
  15. Kwok P, Waldeck A, Strutz J. How do metallic middle ear implants behave in the MRI? [in German]. *Laryngorhinootologie* 2003;82:13–18.